

NATURAL BALANCE

Dentistry

How Natural Balance Dentistry Can Improve Whole Horse Health

Dr. Rhiannon Fenton, DVM, CAC, CVA, CVFT

Pain—it's usually the first thing that will prompt a phone call to the vet. The last place we often look is the mouth. Holistic medicine understands that everything begins with the mouth—starting with what is being fed and then how the mouth works mechanically to masticate those foods. But more important, and the least-recognized factor, is how the mouth relates to the entire body from head to toe, nose to tail.

First, one must understand that every tooth is the ending of a nerve. Teeth serve as guidance for neurological function, body mass, motion, and eating. Each tooth opposes another tooth either above or below it and creates a synaptic connection similar to a spark plug. Teeth-touching creates nerve impulses and transmission of signals through various acupuncture meridians within the body that direct organ function, sensory apparatus, and proprioception (balance and awareness of body movements statically and dynamically). When teeth do not touch each other properly, the transmission of such information does not occur.

With this paradigm, it is clear why horses that are power floated or treated incorrectly can develop a myriad of conditions within the body days, weeks, months, and even years later. If you're lucky, your horse will only experience a mild colic. If you're not so lucky, it can be a downward spiral of events leading to death within six months. In the middle of those two scenarios is the more typical situation: a slow, insidious, and degenerative breakdown of the body that is hard to identify in retrospect and often goes unrecognized until the damage has been done.

So what is an owner supposed to look for to indicate there could be a dental problem? Pretty much any problem in the body. Health begins first and foremost in the mouth, and when the balance of the mouth has been damaged, expect problems elsewhere. These issues include but are not limited to:

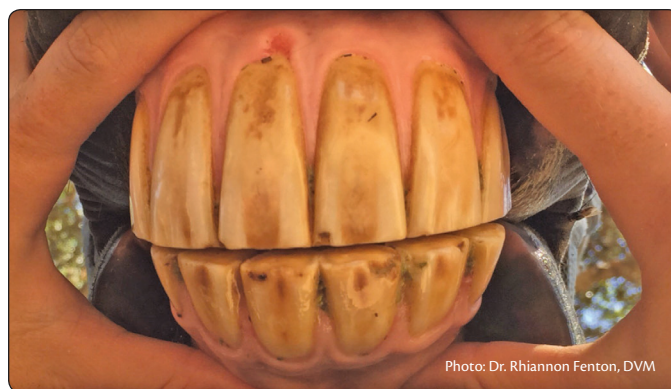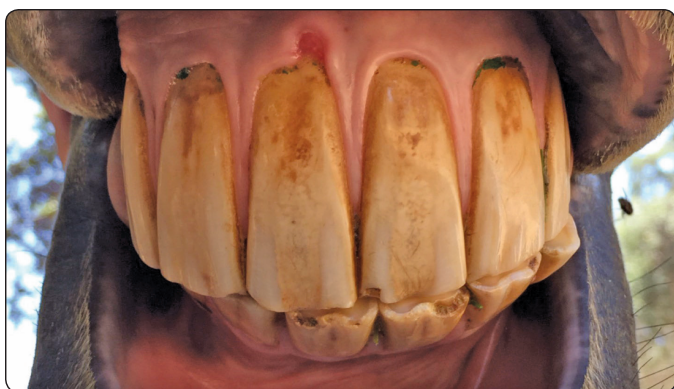- ◆ asymmetrical gait
- ◆ high/low heels and shoulders
- ◆ irreparable hoof issues
- ◆ joint damage/pain
- ◆ tendon and ligament tears

- ◆ muscle soreness, atrophy or hypertrophy
- ◆ chiropractic adjustments not sticking
- ◆ not tracking straight or tight-rope walking
- ◆ inability to pick up leads easily, flex, extend, or engage hind end
- ◆ lugging on one rein
- ◆ poll pain, lack of flexion, or extension at the poll
- ◆ organ dysfunction (i.e. colic, liver, or kidney issues)
- ◆ weight loss or gain
- ◆ excessive eye drainage or tears
- ◆ and the list goes on...

Dental health and wellness involve more than just a visual or tactile inspection of the mouth. Much information can be gained about the mouth by assessment of body conformation, posture, and the ability or inability to move freely during work or exercise. Holistic veterinarians and professionals certified in the science of Natural Balance Dentistry (NBD), developed by Spencer LaFlure, are able to recognize the asymmetry and interrelationships among external facial features, internal dental architecture or pathologies, and abnormal posturing or gait. Understanding the significance of these components and how they relate to function provides crucial information for diagnosis of ailments in the entire body, and not just for dental-related issues.

What makes Natural Balance Dentistry so different?

It seeks to observe deviations from normal balance for each individual and restores balance in a way that is “normal” in each horse. No two horses will ever be the same. Each has its own unique characteristics, quirks, and anomalies—the same is true for mouth and dental architecture. For example, some horses are born with a twisted maxilla that will cause a slight curvature of the incisors up to



This is a before and **after** Natural Balance Dentistry treatment. Dr. Fenton did not try to make this aesthetically perfect, as that would be detrimental to this specific horse's natural, anatomical conformation and biomechanics of the mouth. This horse naturally has a wedge up to the left. It is important to support this in order to maintain this horse's balance, as that is what is normal for her.

one side. A Natural Balance dental practitioner knows to allow and support this structural defect because that is what is anatomically correct for that horse. It would be detrimental to the whole body to try and make the occlusion aesthetically perfect by straightening it out.

The horse will be unable to carry itself straight, properly approach jumps, or perform dressage in both directions with equal finesse.

There are many nuances to NBD that traditional dentistry has not yet learned to appreciate. Some follow below:

Suggested Equine Acupuncture Meridian Tooth Relationship

	Molars	Premolars	Canine	Incisors	Incisors	Canine	Premolars	Molars
Joints & Vertebrae	*Left: S1, hip, hock **C7, T1, T5, T6, S1, S2, T11, T12, L1	*Right: shoulder, knee, ankle **C5, C6, C7, T3, T4, L4, L5	*Not known **T9, T10	*Under study **Sacrococcyx, L2, L3, S3, S4, S5, Coccyx	*Under study **Sacrococcyx	*Not known **T9, T10	*Left: S1, shoulder, knee, hock **C7, T1, T5, T6, S1, S2, T11, L1	*Right: hip, hock **C7, T1, T5, T6, S1, S2, T11, T12, L1
Sense Organs Other	**Inner Ear, maxillary sinus	**Ethmoid cells	**Eye	**Frontal Sinus	**Frontal Sinus	**Eye	**Ethmoid cells	**Inner Ear, maxillary sinus
Internal Organs	**CNS, Psyche, Mammary gland							**CNS, Psyche, Mammary gland
Internal Organs	**Right: heart, duodenum, stomach; terminal ileum, pancreas, esophagus.	**Right: Lung, large intestine	**Right: liver, biliary ducts; gall bladder	**Right kidney, bladder, uterus, prostate, rectum, anus, genital	**Left kidney, bladder, uterus, prostate, rectum, anus, genital	**Right: liver, biliary ducts, gall bladder	**Left: lung, large intestine	**Left: stomach, heart, duodenum; spleen, esophagus, jejunum, ileum, pancreas
Endocrine Glands	**Anterior pituitary, Parathyroid, thyroid	**Thymus, posterior Pituitary	**Intermediate Lobes of the pituitary	**Pineal	**Pineal	**Intermediate Lobes of the pituitary	**Thymus, posterior Pituitary	**Anterior pituitary, Parathyroid, thyroid
Tooth								
Tooth								
Endocrine Glands		**Ovaries	**Testes	**Adrenals	**Adrenals	**Testes	**Ovaries	
Internal Organs	**Right: heart, stomach; terminal ileum, pylorus, pancreas, ileo-cecal, esophagus, lung	**Right: Lung, large intestine, stomach, pylorus, pancreas	**Right: liver, biliary; gall bladder	**Right kidney, bladder, uterus, prostate, rectum, anus, genital	**Left kidney, bladder, uterus, prostate, rectum, anus, genital	**Right: liver, biliary ducts	**Left: lung, large intestine, gall bladder, stomach, pylorus, pancreas	**Left: stomach, heart, duodenum; spleen, esophagus, jejunum, ileum, lung, large intestine, ileum, ileocecal region
Other	**Energy metabolism, peripheral nerves, arteries, veins	**Mammary gland, lymph vessels					**Mammary gland, lymph vessels	**Energy metabolism, peripheral nerves, arteries, veins
Sense Organs	**Ear, ethmoid cells	**Maxillary Sinus	**Eye	**Frontal Sinus	**Frontal Sinus	**Eye	**Maxillary sinus	**Ethmoid cells
Joints and Vertebrae	*Left: S1, stifle, hock, fetlock **C7, T1, T5, T6, S1, S2, C5, C6, C7, T3, T4, L4, L5	*Right: shoulder, knee, hock **T11, T12, L1	*Not known **T9, T10	*Under Study ** Sacrococcyx, L2, L3, S3, S4, S5, Coccyx	*Under Study **Sacrococcyx, L2, L3, S3, S4, S5, Coccyx	*Not known **T9, T10	*Left: S1, shoulder, knee, hock **T11, T12, L1	*Right: stifle, hock, fetlock **C7, T1, T5, T6, S1, S2, C5, C6, C7, T3, T4, L4, L5

*Suggested from noted correlations documented in NBD
**Suggested from traditional Acumeridian Tooth-Organ Relationships in humans

Chart created by Dr. Fenton, DVM and Sara Twickler, EqNBD

1) Anything that restricts motion in the mouth restricts motion in the entire body. (Figures A and B)

For example, waves in the mouth, which are man-made by improper dentistry, restrict motion of the jaw. Typically a wave-mouth is made by power tools that are difficult if not impossible for even the most adept dentist to keep from bouncing around in the horse's mouth. Due to this, there will be an inconsistent, unlevel tooth height along the molar arcades. These uneven teeth heights create waves that will literally lock up the movement of the jaw since it normally has only $\frac{3}{8}$ " to move in the first place. Horses with this condition are likely unable to flex at the poll properly, tend to overflex, get locked into one position, or get stuck into an abnormal frame, which hurts their body further. They may also fight the rider for the reins because they are locked up in the jaw. This is a prime example of a horse in need of balancing, not "floating," other power-tool dentistry techniques or tie-down equipment.

The horse in Figure A can easily move his head up and down with free sliding movement of the jaw. Imagine the horse in Figure B trying to flex at the poll and move his head up and down. It won't be able to with ease. The waves in his teeth act as parking blocks, preventing forward and backward sliding motion of the jaw. This is why forcing a horse "into frame" or tying them down with any type of equipment is entirely damaging and the wrong thing to do.

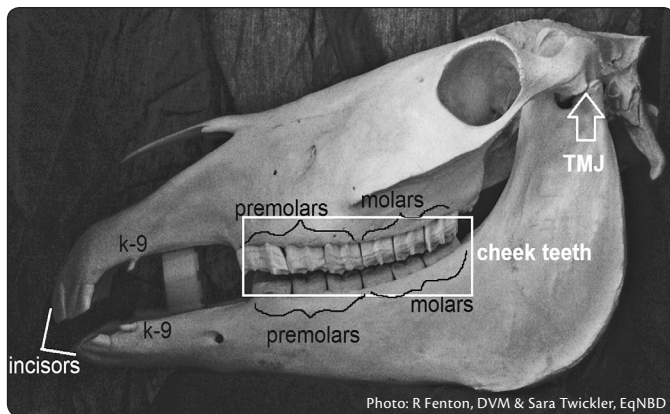


Figure A - Normal premolar and molar alignment, which can allow for smooth motion of the jaw back and forth and smooth movement through the rest of the body.




Figure B - Wave mouth of premolars and molars, which will not slide smoothly back and forth thus creating restrictions in flexion and extension throughout the body.

2) By creating a "bit seat," the balance and stability of the jaw is removed. (Figures C and D)

There is a three-point balance in the mouth, comprised of the first three molars. These specific teeth are the first that form during embryonic development. Their job is to provide that vital synaptic connection discussed earlier, help keep the TMJ in proper positioning, and guide alignment as the horse is forming in utero. If at any point in the horse's life, he can't find that balance because it has been removed by creation of a bit seat, the rest of his movement will be out of balance as well. Think further on down the road—abnormal joint wear, premature arthritis, torn ligaments, damaged cartilage, thousands of dollars spent on X-rays, ultrasound, joint injections, PRP, IRAP, and stem-cell therapy to chase an issue, when it actually resides in a place you haven't even looked!



Figure C - Outlined in red is demonstration of a bit seat creating a gap in contact between the premolars. The horse relies on the ability of ALL teeth to make as much surface area contact with each opposing tooth above or below without any gapping. Remember, each tooth is the calcified ending of a nerve. The entire tooth needs to touch its opposing tooth in order to have that synapse and "spark plug" type effect previously discussed. The meridian chart (Page 17) reviews which organs, muscles, joints, etc., will be negatively affected by a bit seat or gap being created in any tooth.

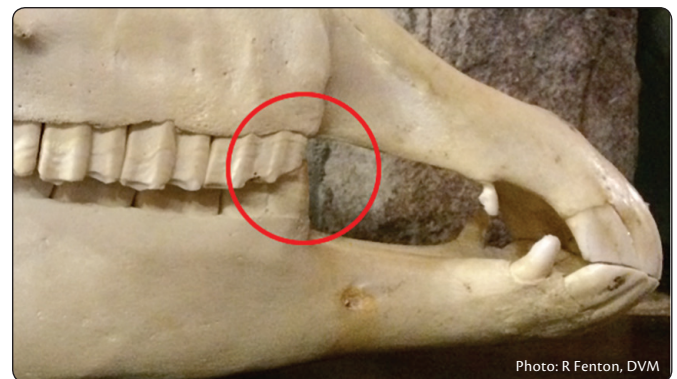
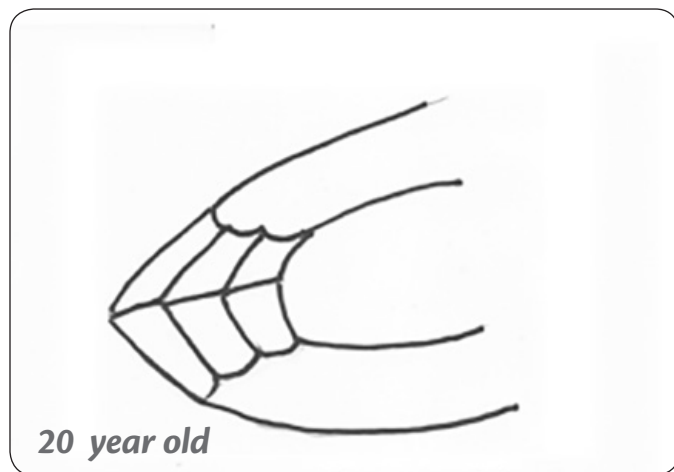
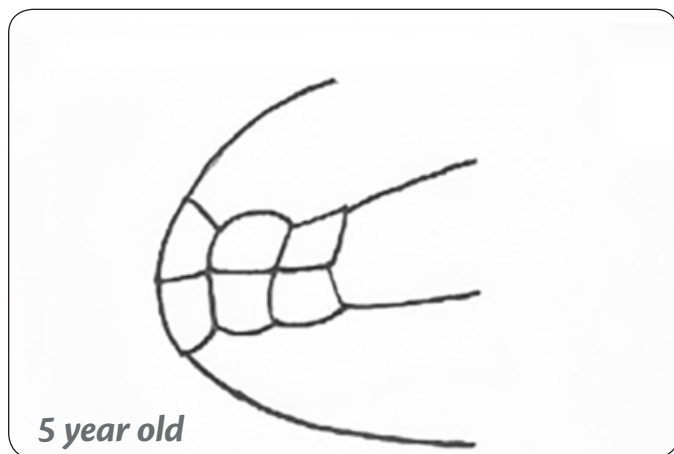


Figure D - This is what a mouth without a bit seat looks like. There is no gap in the premolars. Full tooth-touching and synaptic firing occurs for proper biomechanics to function.

3) Mature horses over the age of 5 years should have the incisor length and angle of a 5-year-old their entire life.

Most of us have come to understand that the length and angle of the hooves should be the same throughout a horse's life. The teeth are no different. Horses naturally wear their teeth by grazing 16–18 hours a day on a variety of plant species. The abrasiveness of plants and soil plays a dynamic role in tooth wear. The domesticated horse is kept mostly in a stall or confined area and exposed to one or two types of processed cut hays without the ability to roam, graze, or wear their teeth as nature intended. This is what disadvantages the domesticated horse and ultimately contributes to dental issues. Add to this scenario power floating, incorrect dentistry, poor nutrition or hoof care, or bad saddle fit, and the horse will have even more systemic issues.



A horse that has had Natural Balance Dentistry as early as possible (2–3 years of age) and regularly throughout its life (once or twice a year) will maintain a closer incisor angle of a 5-year-old horse. This is more desirable as proper length and angle of the incisors dictate the motion of the rest of the mouth, jaw and temporomandibular joint (TMJ).

4) Feeding in upright corner feeders and raised troughs are damaging to your horse's dental, gastrointestinal, and chiropractic health. (Figures E and F)

By feeding upright instead of on the ground, natural tooth wear from sliding of the jaw back and forth during grazing motion does not occur. With the head upright while chewing, transverse grooves are made in the molars that create gridlock. This restricts jaw movement (See 1.). If a horse suffers in the mouth, trying to get him to round his back, move off the haunches, and lift his body up and carry himself will be anatomically impossible. Don't force him into what is considered a correct position with draw reins, side reins, and other equipment. There is a reason he can't do it, and that reason is that he lacks balance in the mouth.

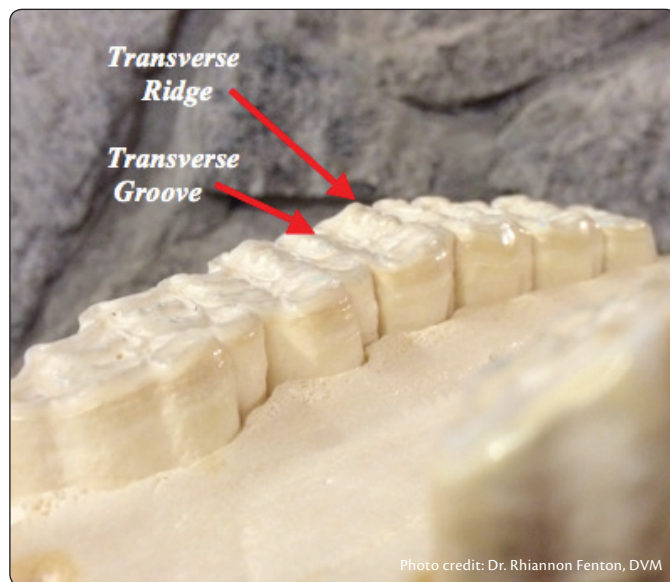


Figure F - Same skull as above. This is a view of the upper molar arcade, when the skull is placed upside down. It is easy to see the grooves and ridges created that were pointed out in the previous picture.

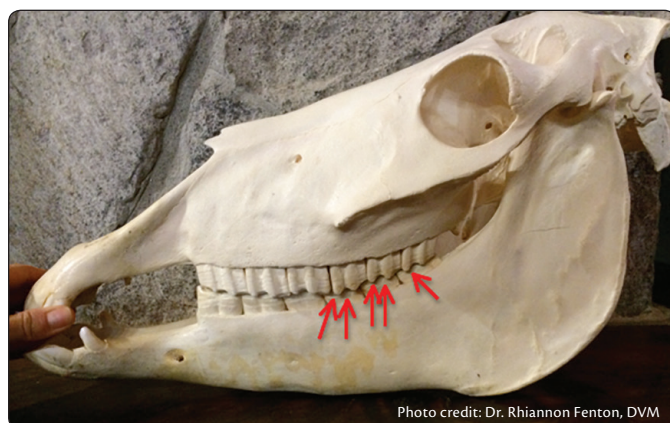


Figure E - The arrows on the skull of this horse exhibit accelerated transverse ridges (ATR). The horse was likely fed in an upright position for many years. The critical sliding motion of the jaw forward and back while grazing food from the ground and then raising the head to resting position to chew food did not take place. This creates lack of natural wear forward and backward, excessive chewing laterally in the same position and can contribute to the grooves and ridges called ATR. ATR will restrict flexion and extension at the poll, rounding of the back and moving off/engaging the haunches.

5) The whole reason dentistry should be performed on a horse is to balance the temporomandibular joint (TMJ). (Figures G and H)

There are specific sensory receptors in the body that detect and respond to the posture, position, and movement of the horse. These receptors and several highly important nerves—responsible for swallowing, respiration, heart rate, and perception of balance in the brain—travel through the TMJ. If the TMJ or jaw is not properly aligned, it pinches the nerves, shuts off the receptors, and short circuits many bodily movements resulting in difficulty swallowing and chewing, short strides during movement, not standing square, difficulty in taking leads, asymmetrical body structure, muscle atrophy, lameness, and the list goes on. Typically, traditional vets will perform on the mouth and force the mouth to move the way they think is appropriate, without any regard to the TMJ or what is anatomically and biomechanically correct for that horse.

To do right by the horse, holistically, a professional should follow the individual horse's dental anatomy in order to restore and/or maintain the inherent dental architecture and biomechanics of that individual's mouth. This helps the TMJ stay balanced and in correct anatomical alignment with the nerves and receptors that run through it. The process of chewing food,

healthy digestion, and fluidity of body movements will follow smoothly from there. (Figure H)

There are many other principles to consider when guiding a horse's mouth to function properly for the sake of the entire being. My best advice is to not hire a veterinarian who has a huge rig, uses power tools, a head stand, or likes heavy sedation. There is something to be said for doing things by hand and taking the time to do the job right—even if it takes longer. Having an eye and an appreciation for how all things come together in the body will prevent problems later on and decrease vet costs. People may say dentistry is expensive but bad dentistry is even more expensive. Do it right the first time. Your horse will thank you and you may have some money left over in your wallet.

Dr. Rhiannon Fenton is a Southern California native and currently resides in Calabasas. She was introduced to horses at a very young age and fell in love immediately. Horse training soon became a passion and a very successful endeavor by the age of seventeen. Dr. Fenton holds degrees and certifications in veterinary medicine as well as chiropractic, acupuncture, food therapy, Reiki energy healing, and Natural Balance Dentistry. She offers highly effective and custom-tailored specialty treatments for horses and many other species, her goal being to unlock the body's potential to heal itself, thereby allowing healing to occur innately, gently, and safely.

Figure G

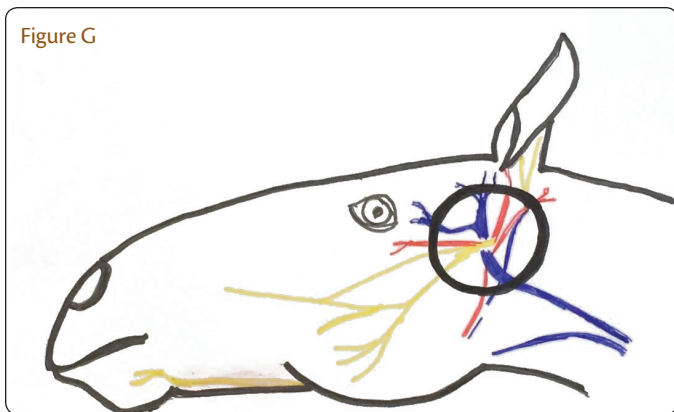


Figure H

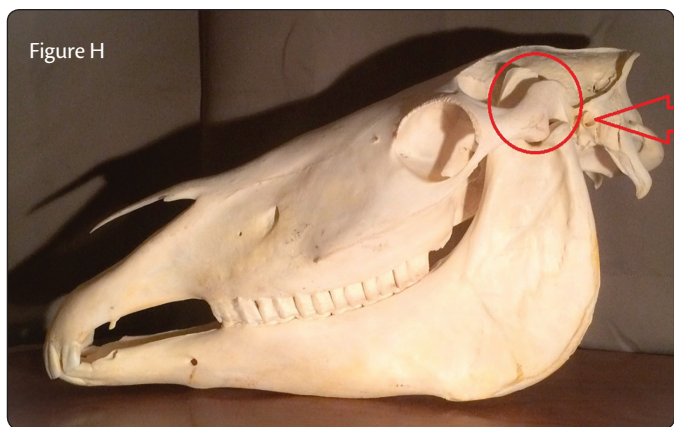

Figure H - The circled area indicates where the temporomandibular joint is located. (Figures G and H) All the nerves that run through it must not be pinched or altered in any way. Otherwise, vital messages are not conveyed or are short circuited to the rest of the body. NBD seeks to keep the TMJ balanced so it can serve as an open highway for nerve pathways with free flow of information. This supports proper bodily function of all internal organs and correct movement of all joints everywhere.